

# CASE SUMMARY: CRYOPRESERVATION OF A-1598

On Friday, October 7, 2005, a 60-year-old diabetic Alcor member was discovered unconscious in his California home by his significant other, also an Alcor member. No one knows how long he had been lying there, but paramedics were immediately called to the scene. He was evaluated and treated at his local hospital. Alcor's northern California transport team members were among the first responders to the emergency call. Several local team members were deployed to the hospital with stabilization equipment while an Alcor Central team was dispatched along with its emergency transport vehicle from Arizona.

A standby was performed and lasted for several days. Doctors initially suspected that this member may have fallen, hit his head and suffered some brain damage. An MRI revealed that brain damage might have indeed been present, although it probably resulted from a medical condition other than the fall. When it became apparent that the member was not recovering, his significant other made arrangements for an air ambulance to safely transport him to a hospice located in Arizona within five miles of Alcor's facility. Once he arrived in Scottsdale, Alcor Central's transport team was immediately de-

ployed to assess the situation further. Quick deployment was crucial because it was merely eight hours after landing at the airport that the member's heart stopped. He had family, friends, and Alcor personnel at his side when the moment came.

The patient stabilization began immediately. The cryoprotection was begun a little over an hour later and proceeded smoothly, with few complications. Vitrification of the brain was achieved; and the subsequent cooling resulted in few fractures being detected, and those were at the lowest temperatures ever recorded. This was one of the best cryopreservation procedures ever implemented at Alcor.

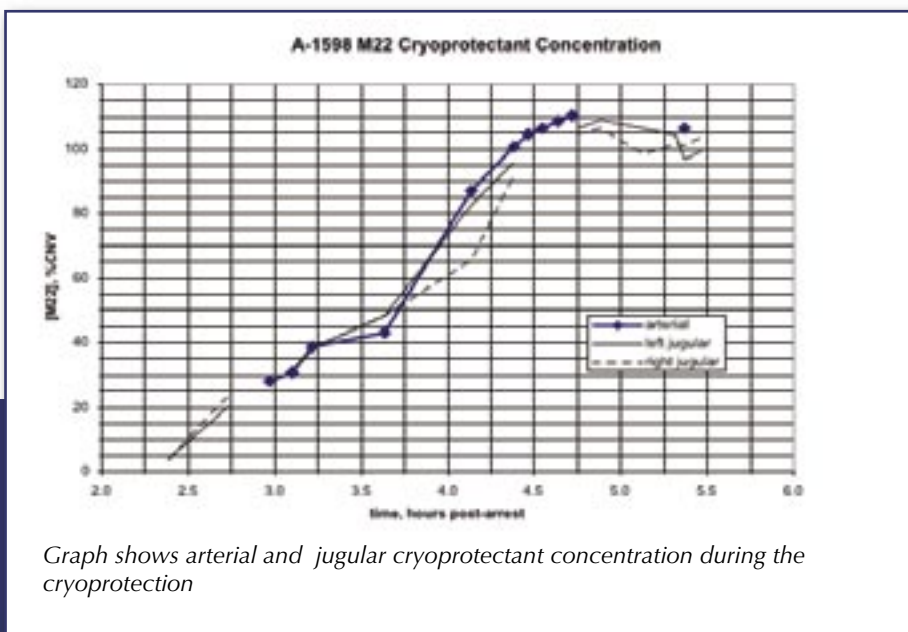
First and foremost, the efforts of this member's significant other to get him into a local hospice contributed tremendously to the quality of the subsequent cryopreservation. Alcor was able to begin its procedure immediately with some assistance from the hospice staff, and team members provided care within Alcor's emergency transport vehicle during the rapid transit to Alcor. In the end, this patient received the best M22 perfusion to date largely due to the fact that he was close to Alcor when he needed to be.

The challenges in this case were part hu-

man error, part equipment deficiencies. First, the patient was too large for Alcor's mechanical cardiopulmonary support devices. Alcor was required to continue manual compressions using the Ambu Cardiopump. Although having the Ambu Cardiopump available enabled Alcor to continue circulating much-needed oxygen and stabilization medications, it was less effective than the mechanical cardiopulmonary support would have been.

Another challenge was discovered during a routine vascular resistance test conducted during the cryopreservation process, where a cannula was discovered to be clamped. This surgical oversight resulted in slightly less shrinkage in the right brain hemisphere, but the hemisphere is still believed to have achieved target concentrations needed to vitrify. Continuing with routine checks performed at regular intervals and improving the surgical training available to team members will avoid unintended oversights of this type.

Finally, the crackphone device was temporarily unavailable for monitoring this patient's cooldown because it was being used with another patient. As Alcor grows, dual capability for multiple patients needs to be expanded to include all aspects of the cryopreservation procedure. ■



Graph shows arterial and jugular cryoprotectant concentration during the cryoprotection