

Alcor A-2091 Case Report



Prepared by:

**Aaron Drake, NREMT-P, CCT
Medical Response Director - Alcor Life Extension Foundation**

and

**Catherine Baldwin
Standby Team Leader – Suspended Animation, Inc.**

with

Cryoprotection Summary by Hugh Hixon

November 2012

Alcor A-2091 Case Report Contents:

1. Overview.....	Page 3
2. Personnel.....	Page 3
3. Pre-Deployment.....	Page 4
4. Deployment.....	Page 5
5. Stabilization, Field Surgery and Perfusion.....	Page 6
• Stabilization cooling graph	
6. Transport.....	Page 9
• Transportation temperature graph	
7. Surgery.....	Page 10
8. Cryoprotection Summary.....	Page 10
• Refractometry graph	
• Cryoprotection temperature graph	
• Cryoprotection pressure graph	
• Cooldown to -20° C graph	
• Cooldown to -80° C graph	
• Cooldown from -80° C to LN2 graph	
9. Timelines.....	Page 15
• Stabilization	
• Cryoprotection	
10. Issues and Actions.....	Page 17

1. Overview

A-2091, an Alcor member living in Southern California, was diagnosed with a glioblastoma in 2010. Chemotherapy and medication administration were prescribed; however they were discontinued in June 2011. With the assistance of a local home healthcare agency the member received 24 hour care within the comfort of her home. In mid-June, Alcor prepared and shipped a mini-med kit to her home in the event of a sudden clinical death.

Arrangements were made with Suspended Animation (SA) to provide standby services when required. These arrangements were made at the specific request of the family who agreed to pay any and all additional costs from early deployment. Alcor's Medical Response Director, Aaron Drake, arranged a charter flight and made a special arrangement with the Health Department so that we could call after hours to secure a transit permit. Aaron visited the patient and her family at her home in late July, while also meeting with a nearby mortuary and working out logistic details.

SA initiated a standby on August 9, 2011 with at least two team members on site at all times. Shortly before noon on August 18, it was clear that clinical death was imminent. The charter flight was set in motion, but a dust storm in Scottsdale/Phoenix delayed its departure—fortunately only briefly.

Immediately following pronouncement, the patient was cooled quickly over the first hour after cardiac arrest. This cooling rate appears to be one of the two fastest yet achieved. No one was answering the phone at the Health Department; however the private, after-hours number prompted a quick return call which allowed the paperwork to be processed, despite the office being closed. The patient was loaded onto a private plane at 8:57pm and reached Alcor at 10:22pm. The surgery was challenging due to extensive medical issues, however target cryoprotectant concentration was reached in the brain. Member A-2091 became Alcor's 107th patient.

2. Personnel

Field stabilization team: Aaron Drake, Alcor's Medical Response Director; Catherine Baldwin, Suspended Animation's Standby Team Leader; three SA staff members, a cardiac perfusionist, and a cardiothoracic surgeon.. They were supported by Max More, CEO; and Steve Harris, M.D., Chief Medical Advisor.

Alcor's surgery team: Dr. Nancy McEachern, DVM, Surgeon; Aaron Drake, NREMT-P, Surgical Assistant; Hugh Hixon, Cryoprotection Perfusionist; Steve Graber, Assistant Cryoprotection Perfusionist; Max More, Ph.D., Scribe; R. Michael Perry, Ph.D., Cooldown

Coordinator; Bonnie Magee, Refractometry. Surgical support staff: Bruce Cohen and Richard Cremeens.

3. Pre-Deployment

A-2091 was physically active and healthy prior to being diagnosed with a glioblastoma multiforme in her brain during the spring of 2010. Subsequently, she underwent fifteen months of conventional tumor therapies and one experimental medication. These treatments may have slowed the course of the tumor but were unable to prevent its spread. Slowly, she was losing her ability to walk, talk and eat.

Alcor Life Extension Foundation (Alcor) was notified in June 2011 that the member had decided to discontinue further tumor treatments. A local concierge medical provider, Premiere Home Health Care, coordinated her physicians, nursing, physical therapy and other support in her home.

Over the next few weeks, Alcor's Medical Response Director made advance preparations with a local funeral home, a private air charter for transport and the Orange County Health Department for expedited paperwork, even in the event these were needed after-hours. Local Alcor volunteers were on alert with a vehicle and equipment nearby in the event of a sudden and unexpected clinical death.

Alcor notified Suspended Animation (SA) that member A-2091 was discontinuing treatment for her terminal condition and might require SA standby services soon. Alcor monitored the situation closely and informed local volunteers and officials as changes precipitated. SA also began coordinating preparations directly with the member's medical providers and family. The family agreed to cover all extended costs associated with having SA deploy a full team to the home well in advance to handle the patient's standby, stabilization, surgery and field perfusion.

SA visited the member and her family and positioned a vehicle and equipment to support stabilization, surgery and perfusion at the patient's home. Staff from Premiere and SA worked closely over the following weeks to monitor the patient's condition and create an action plan.

The patient's condition declined incrementally over June and July; she lost her ability to communicate verbally and to move on her own, and spent more and more time sleeping. Her physician ordered placement of a supra-pubic urinary catheter and a peripherally inserted central catheter.

By early August, the patient was having increasing difficulty swallowing and fewer lucid periods, although her vital signs and blood test values remained within normal ranges. Her

neuro-oncologist said her brain scans indicated tumor intrusions further into her brain that would likely begin to interfere with her body's basic life support functions.

On the evening of August 8, 2011, the member's medical staff and family felt that her death would occur within a few days although it was clinically possible for her to survive much longer. The member's spouse requested that SA deploy to avoid any risk of not having a full team onsite at the time of clinical death. SA sent a surgeon, a cardiac perfusionist, two staff EMTs and two additional staff to begin the standby at the patient's home on August 9.

4. Deployment

As the team arrived, the patient was sitting up, alert and responsive. She was still able to swallow soft foods and thick drinks, but was receiving minimal oral hydration and nutrition. Her vitals remained steady. Her temperature was normal. Blood pressure was 122/98. Pulse 91. Her oxygen saturations were 96% with a nasal cannula delivering oxygen from an oxygen concentrator. Respirations were 23 per minute. A blood draw and analysis in the afternoon showed lab values largely within normal ranges.

In pre-planning, nearby funeral homes either had no room suitable for surgery or declined to support the case "on the advice of corporate legal counsel." The closest cooperative funeral home was nearly an hour's drive away from the patient's home and from the closest airport. If the patient had to be moved there for surgery and perfusion, it would result in unnecessary ischemic time, add dependencies on funeral home personnel and impose extended transport times in traffic.

The member's home had a clean, well-lit and air-conditioned garage that was barely 30 feet from the room where she was being cared for. The member's spouse agreed to have SA set up in the garage space for performing stabilization, surgery and field perfusion.

After cleaning and mopping a suitable space, the team set up the ice bath, AutoPulse and ventilator and the perfusionist prepared the Stockert SCPC mini heart-lung bypass machine. A scrub in area was prepared for the surgeon at a corner sink. A large, deep freezer held enough ice for cooling the patient and insulated coolers were set up to chill the organ preservation perfusate solution and keep stabilization medications cold.

Team members divided into two 12-hour shifts between the patient's home and the closest local hotel, ten minutes away by car. Two Premiere Home Health Care nursing staff also remained with the patient in shifts 24 hours a day.

After determining that the patient's physician would not be readily available to provide a prompt pronouncement of legal death, Premiere obtained independent 24-hour hospice nurse coverage at

the patient's home. The hospice nurses had authority to pronounce legal death, so SA could begin procedures immediately afterward.

Over the next week, the patient continued to remain fairly stable. Her periods of alertness varied but generally grew shorter. Her breathing grew more labored but respiratory rate stayed at 24. Her vitals often dipped precipitously around 2am, as her blood pressure would drop from around 120/80 to 70/60, her pulse would climb from 90 to above 100 and her oxygen saturation would fall from 95% to below 90% if the nasal cannula were dislodged or removed. Since her hydration was minimal, urine output was also minimal and grew concentrated.

On August 15th, the seventh day of the standby, the initial surgeon SA deployed had to return to regular work and was replaced by another SA surgeon. An eight-hour overlap of the incoming and outgoing surgeon was arranged to avoid gaps in coverage. The perfusionist and remaining team members asked to be allowed to remain on the case to see the patient through.

On August 17th, as the patient's health appeared to be declining more rapidly, Aaron Drake flew from Scottsdale to Orange County, CA and arrived at the family's home by mid-afternoon. Over the course of that evening, the patient's breathing grew more labored interspersed with long periods of apnea. By the morning of August 18, obvious mottling appeared on her feet and her lower left leg became cool. Finger and radial pulses were undetectable. All team members were summoned to the house.

That same afternoon, the ninth day of the standby, the patient stopped breathing. The hospice nurse attempted to detect a heartbeat using a stethoscope. After listening for two full minutes and detecting no heartbeat, the nurse pronounced the patient legally dead at 4:12pm on August 18th, 2011.

5. Stabilization, Field Surgery and Perfusion

Immediately following pronouncement, the patient was moved from her bed into the portable ice bath and manual chest compressions were given as she was moved down the hall and into the garage area. The AutoPulse chest compression device was started and ice and circulating water applied to the patient once inside the garage.

The rectal occluder and nasopharyngeal temperature probe were inserted and the EZ IO needle set into the left tibial tuberosity. The PICC line was no longer patent. The patient's nasopharyngeal temperature was 36° C.

Over the first 15 minutes following pronouncement, medications were administered through

the intraosseous line: 200mg Propofol, 50,000 units Heparin, 250,000 units Streptokinase, 300mg Aspirin, 100 units Vasopressin, 1mg of Epinephrine every three minutes, 400mg S-methylthiourea, 500mg Niacinimide, 1.5g L-Kynurenine, 1.5mg Keterolac, 80mg Gentamicin. Over the next 15 minutes, the patient received 100ml of THAM, less than 70ml of Vital Oxy, 250ml of 6% Hetastarch, 100g of Mannitol. Epinephrine continued to be administered every three minutes.

The patient was intubated with a Combitube. Initial insertion encountered resistance. The tube was withdrawn and dried globules of food and mucus were observed in the mouth and on the tube. Visible food was swept from the mouth and the tube was reinserted while mild cricoid pressure was applied. After verification of tracheal placement, approximately 200mls of Maalox was added through the esophageal lumen.

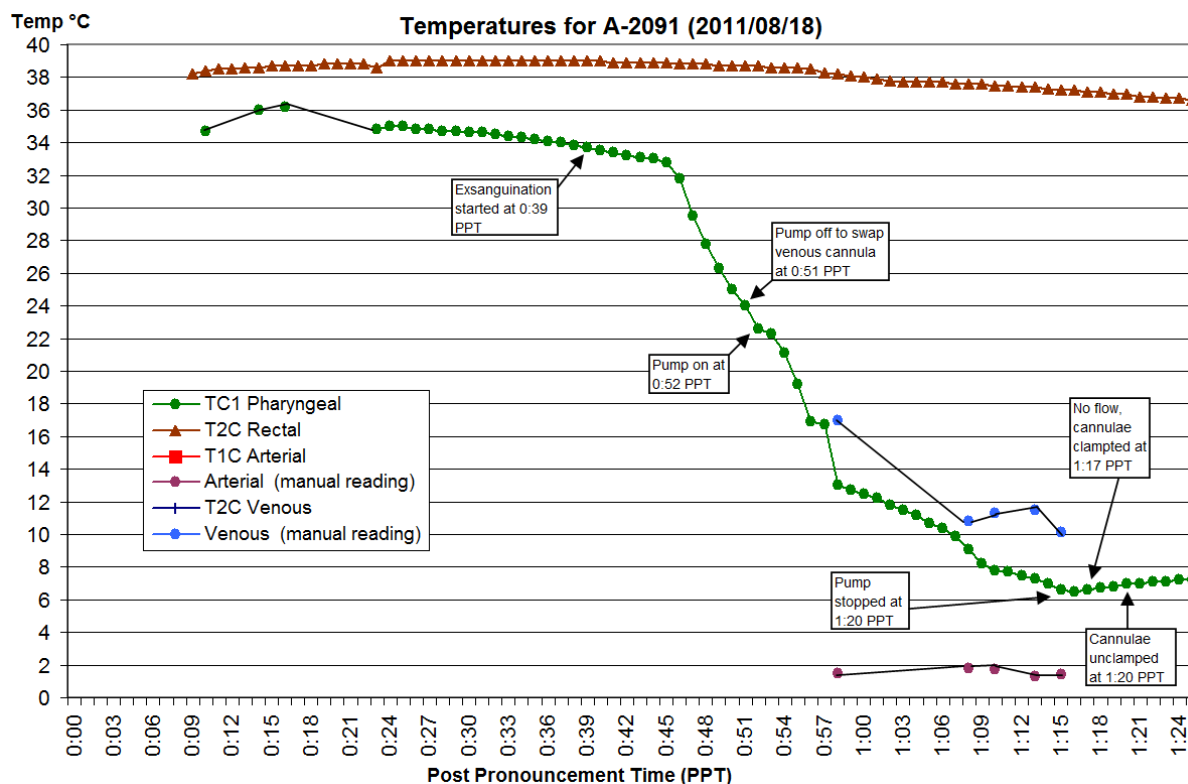
While initial stabilization procedures were delivered, the surgeon scrubbed in. After the first medications had circulated for 15 minutes, the surgeon prepped the right groin area with Chloraprep and Steri-Drape and began a right femoral cut down. Braided silk ligatures were placed around the femoral artery and vein. A longitudinal arteriotomy was performed releasing an arterial spray. The surgeon inserted a 19Fr arterial catheter into the artery. After several attempts to gently advance the catheter into the aorta without success, the catheter was secured in the common iliac artery. A 21Fr venous catheter was placed into the right femoral vein through a longitudinal venotomy. This catheter could not be manipulated into the vena cava and was secured in the iliac vein. Some venous blood flowed into the catheter. The surgeon then connected the catheters to the patient perfusion circuit. The patient's temperature was 34° C.

The perfusionist briefly applied light vacuum assist for venous drainage. As drainage began, the perfusionist filled a serum collection kit from which the patient's stem cells would later be isolated and stored. The remaining venous drainage partially filled a 30 liter waste bag.

Open circuit perfusion continued for 10 minutes with forward flow rates of 700-800mls per minute. The perfusionist maintained circuit pressures between 200-216mmHg. Over this initial period, the patient's nasopharyngeal temperature dropped from 34° C to 24° C.

Attempting to improve flow, the surgeon requested the perfusion pump be shut off and clamped the circuit. He then removed the 21Fr venous catheter to insert a 17Fr catheter into the inferior vena cava. Removal of the initial catheter brought out a large blood clot. The surgeon suggested that the vessel thrombosed pre-mortem. To try to remove additional clot, the surgeon passed a long clamp proximally into the vein to remove another 20-30cc of clot and then inserted the 17Fr catheter and connected it to the circuit. When the pump was turned on again, however, flows did not change significantly. Some abdominal swelling was noted. The pump was turned off for the last time after a total of approximately 35 minutes of perfusion, using 17L of perfusate.

The AutoPulse and ventilator were turned off. Blood tinged fluid and foam were visible in the Combitube. The patient's temperature was just above 6° C. The surgeon clamped the circuit, withdrew the catheters, ligated the vessels and stapled the groin wound closed. The wound closure was small and neat (~3"). Photos were taken.



While the stabilization and perfusion procedures commenced, Aaron called the Orange County Health Department, only to find that their office has closed 12 minutes earlier. As he had earlier obtained the personal cell phone number for the department's director, he called the private number but only received her voice mail. Aaron left an urgent message with the news and requested her assistance in the matter.

He then contacted the private jet company to provide them with a progress report. They asked to be called again when there was approximately one hour remaining before the procedure was finished and the patient would be arriving at the airport. They would alert their pilots now but wait for our phone call before activating them.

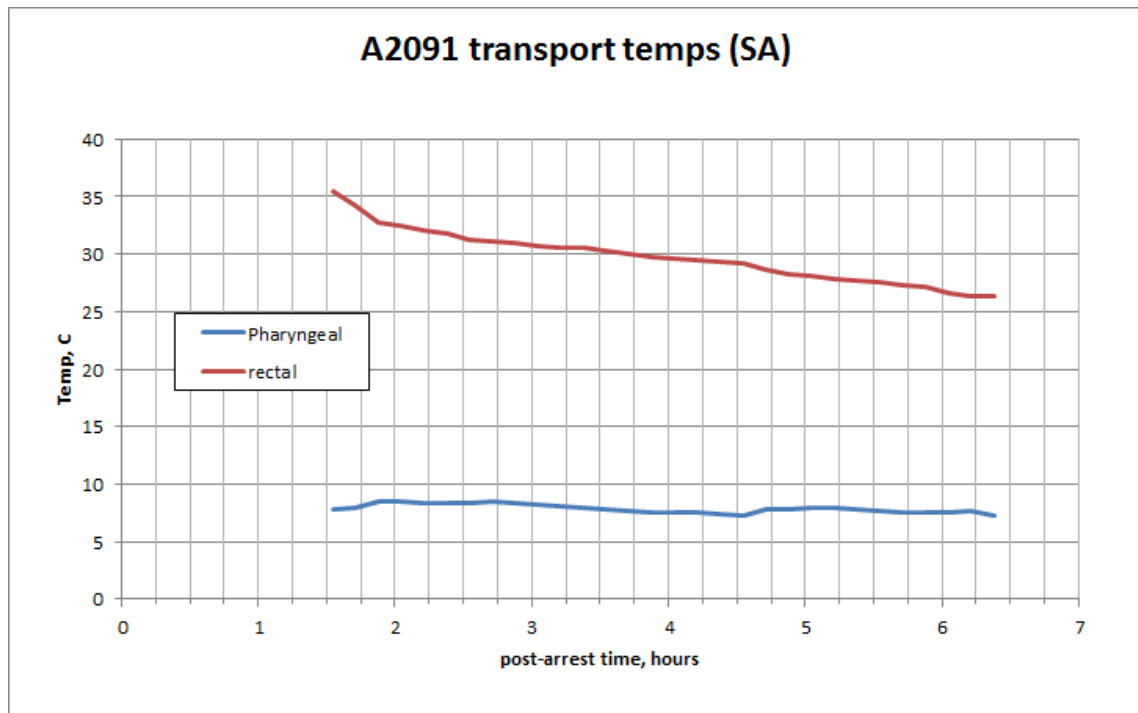
The next call was to the mortuary so they could begin processing the death certificate through the California Electronic Death Registry System. Although it was after hours, he instructed them to send the paperwork electronically anyway as someone from the health department would be there to receive and complete the necessary forms required to issue a transit permit – the legal document that was required for the airplane to cross the California state line.

A short while later, the director of the health department returned the call. She had received the voice message while she was driving home from her office. She immediately turned her car around and returned to reopen the building and begin processing the paperwork personally. As Premiere Home Health Care staff had made arrangements for the patient's physician to sign off on the death certificate, Aaron provided the health department official with the contact numbers for the physician as well as the shipping and receiving mortuary representatives. She said once she had everything completed, she would send both a facsimile and an electronic copy.

6. Transport

Team members removed the patient from the ice bath into a body bag packed with bags of water ice. This bag with the patient was then placed inside a heavier duty body bag and loaded into the vehicle for transport. Catherine and Aaron departed for the FBO section of John Wayne Airport in Orange County with the patient secured in the back of the vehicle. Aaron called the private jet charter dispatcher while en-route only to find the flight had been delayed by a sudden sand storm in Scottsdale prior to departure. Fortunately, the delay was only around 20 minutes.

When the plane touched down at the airport, the patient was driven out to the private charter area on the tarmac and loaded onto the plane for the flight to Scottsdale, accompanied by Aaron. The flight duration was slightly less than an hour and unremarkable. Upon arrival in Scottsdale, Alcor staff members were waiting with the response vehicle to transport the patient the three blocks to the Alcor facility.



7. Surgery

The patient arrived at Alcor's surgery suite at 22:22 and was transferred to the operating table which was covered with a base layer of ice. Additional bags of ice were placed on top of the patient. Aaron Drake disinfected the sternum and an extensive area surrounding it using Betadine surgical scrub applied in expanding concentric circles. Simultaneously, Dr. McEachern shaved and prepped the head in anticipation of establishing burr holes later in the procedure.

Dr. McEachern returned to the chest to perform a median sternotomy. She made a vertical inline incision along the patient's sternum from the suprasternal notch to below the xiphoid process. Aaron placed the guide of the Sarns sternal saw under the sternum at the suprasternal notch. Steve Graber operated the foot pedal on the floor as Aaron lifted and guided the saw to divide the sternum. After the sternum was separated, the chest was opened with Finochietto rib spreaders, exposing the pericardial sac. Dr. McEachern accessed the heart by making an incision through the pericardium.

Dr. McEachern performed an arterial cannulation of the heart by sewing a purse-string suture in the wall of the aortic arch, puncturing the vessel within the purse-string, and advancing and securing the catheter. She then repeated this process for the venous cannulation of the heart, going into the right atrium and advancing the cannula into the inferior vena cava. The purse-strings were tightened around the cannulae and secured.

The procedure took 23 minutes from start to finish. Dr. McEachern noted that the patient had a very thick atrium, bilateral hypertrophy in the ventricles and roughly a 4 cm aortic aneurism.

While the perfusion tubing was connected to the cannulae and the ramp was initiated, Dr. McEachern and Aaron moved to the head. Dr. McEachern made two vertical incisions with a scalpel to expose the skull. The scalp was parted with retractors and Aaron created two burr holes using a Codman perforator. Dr. McEachern cleaned each of the burr holes with a Kerrison rongeur prior to inserting two crack-phone elements bilaterally and a thermocouple which were secured using a surgical stapler.

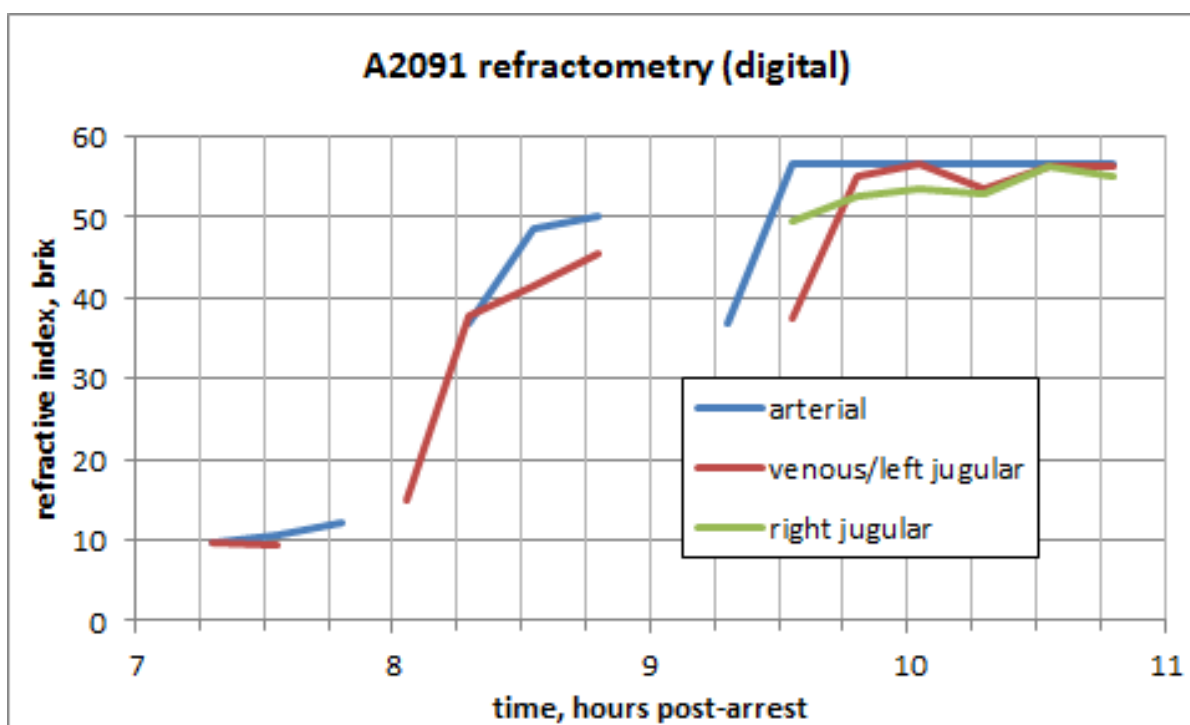
8. Cryoprotection Summary (by Hugh Hixon)

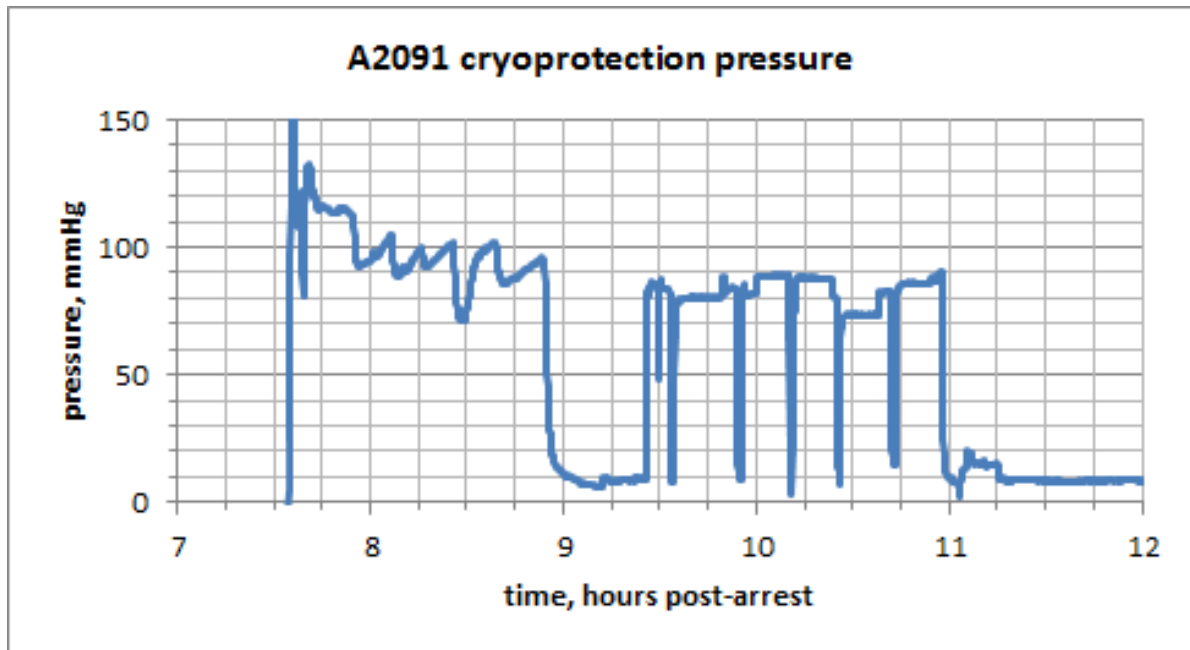
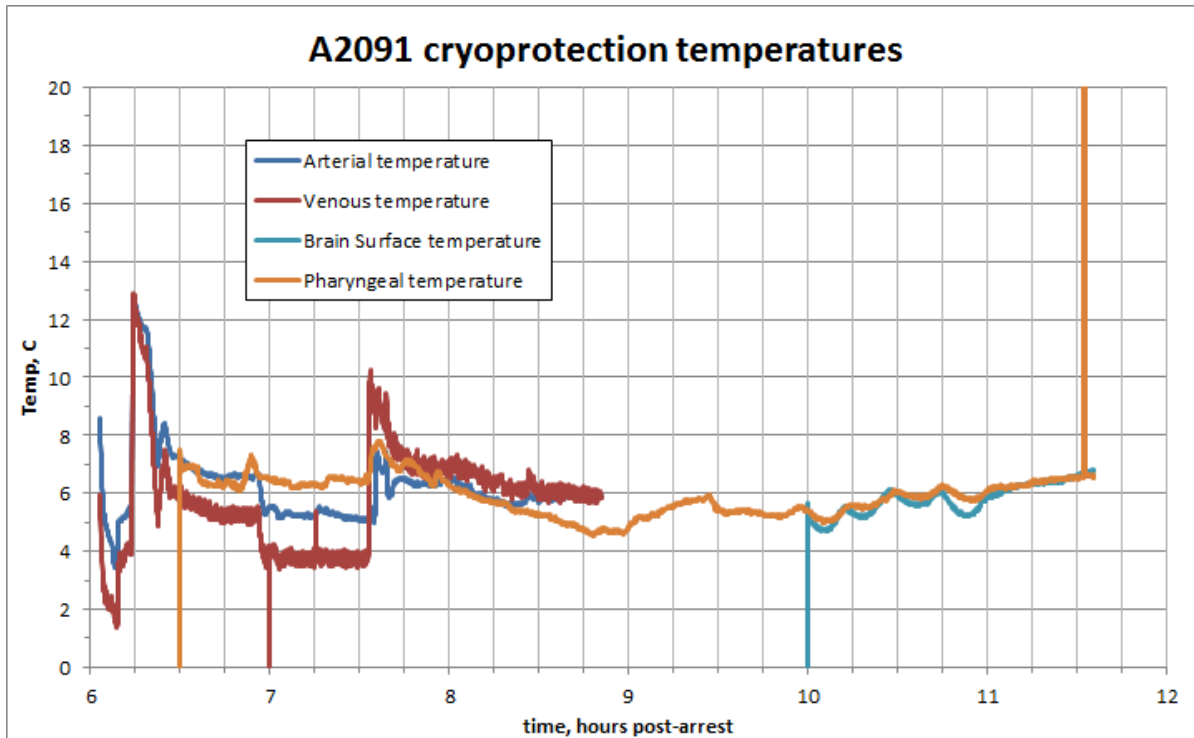
On completion of the right burr hole, clear fluid gushed from the hole, eventually settling down to a leakage of >200 ml/min. There was additional leakage from the left burr hole. Squeezing the neck caused cryoprotectant to gush out of the burr holes. There was no blood in the initial gush of fluid.

The cryoprotectant concentrate pump was adding ~600 ml/min concentrate, running at full speed, but could not maintain the mixing reservoir level. There was almost no venous return and

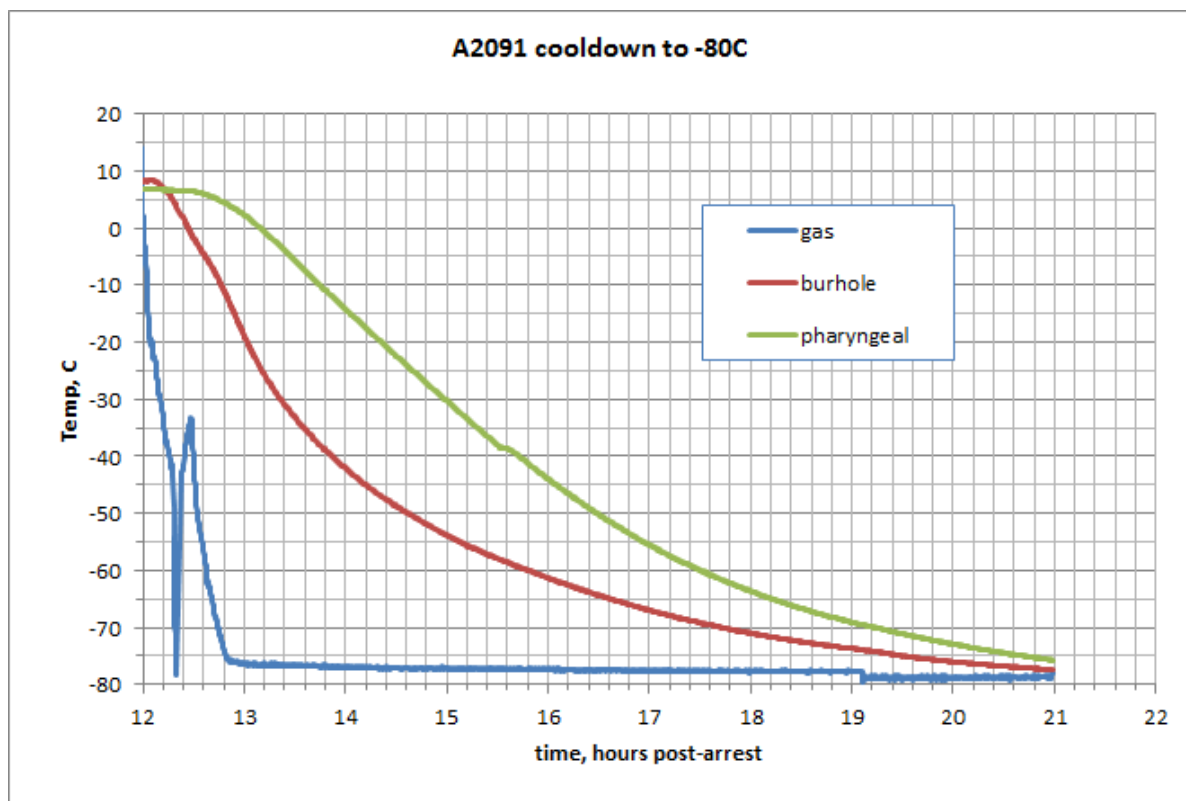
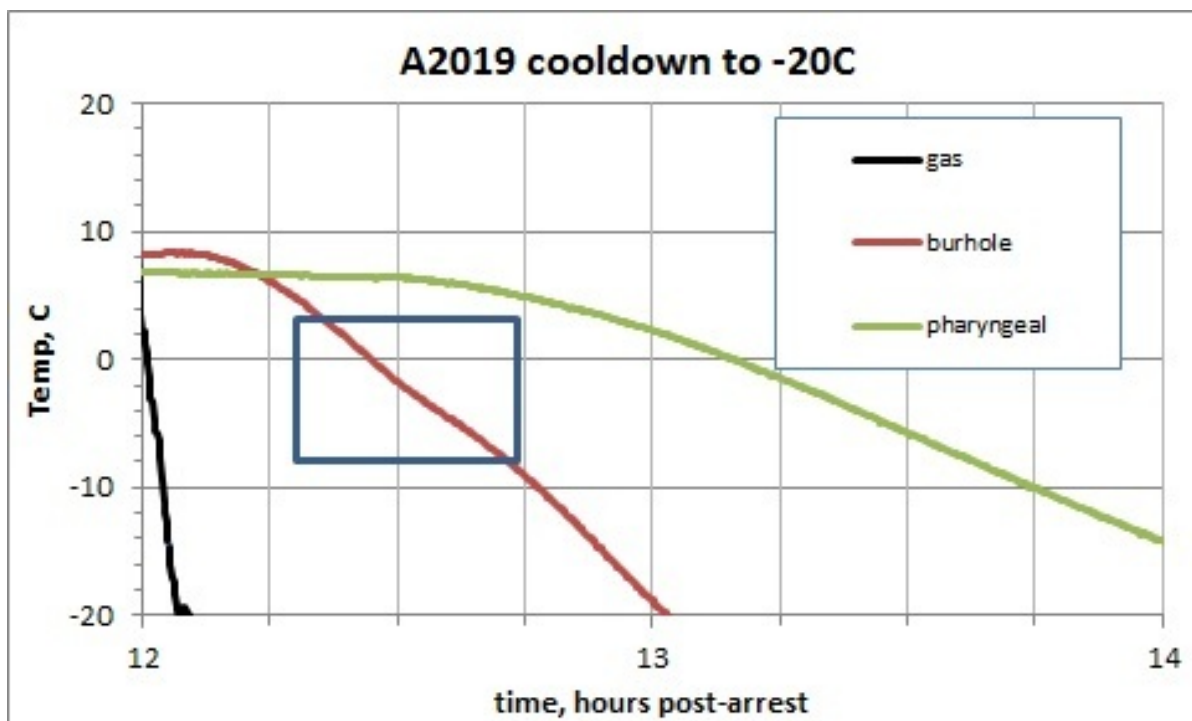abdominal distention was present. The lungs were massively edematous and fluid was leaking from the mouth.

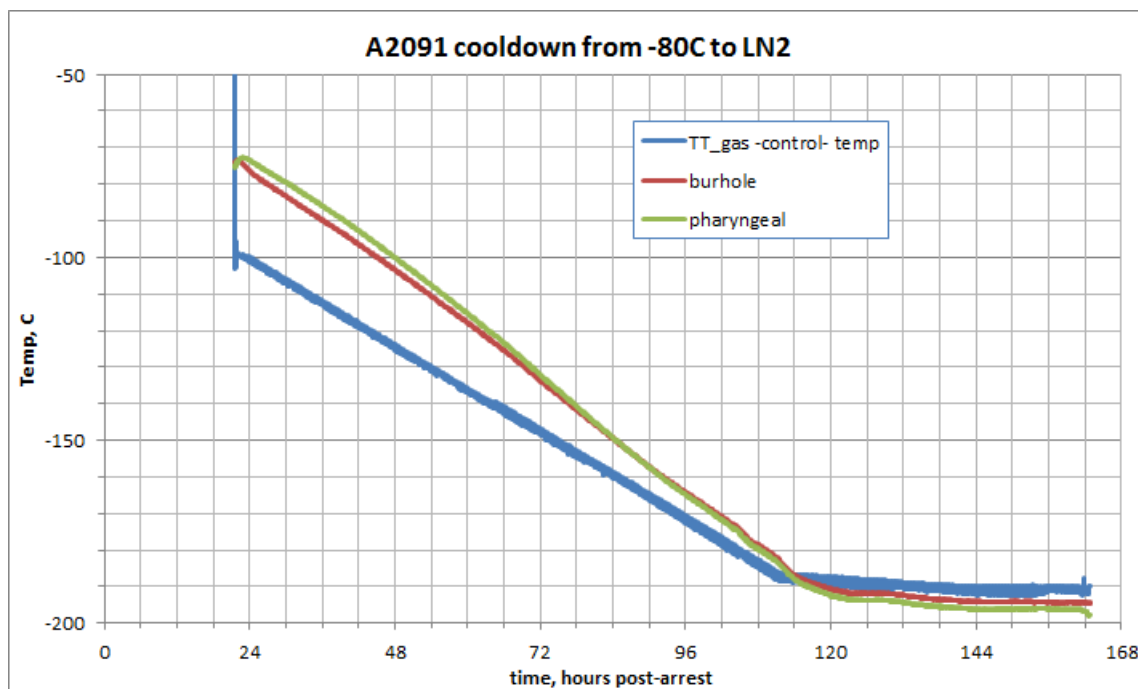
Since the addition pump could not keep pace with the perfusate losses, pumping air was inevitable. Steve Harris, Alcor's Chief Medical Advisor, was contacted and he recommended concentrating on the head, by clamping the aortic arch at both ends. Hugh decided to go further and simply go to straight carotid perfusion, using perfusate on hand for the field neuro step ramp procedure. Aaron raised the carotids while the switch was organized. Perfusion of the whole body was discontinued to assist the carotid cutdown and to avoid pumping air. The first bag selected (bag 7, ~67% CNV) was at roughly the M22 concentration in the WB circuit. Since the patient was on the operating table, the hook for the field neuro bags had to be elevated nearly to the 10' OR ceiling, and was lowered for each bag change.





At the end of the cryoprotection the eyeballs were collapsed (normal dehydration response). The right hemisphere was retracted about 1 cm, under the burr hole, but the left hemisphere under its burr hole did not retract significantly. The skin of the body was tanned, and the head and neck, indicating that the skin was cryoprotected. There is some inflection in the cooling curve that may indicate incomplete cryoprotection (indicated in blue box below).





The glioblastoma was on the left side of the brain surface and had been surgically debulked in the past. There were probably adhesions to the dura and the vasculature was ripped apart when the brain was shrunk by hyperosmolar MHP-2 washout solution or the very hyperosmolar cryoprotectant, and pulled away from the skull, leading to the major leakage observed. This might well result in only partial cryoprotection to portions of the right side of the brain.

The right crackphone element was spring-loaded against the brain (retraction ~1 cm beneath burr hole). The left crackphone element was placed under the dura toward the centerline (no retraction of brain under burr hole). There was a cluster of events on the right side in the -120° C to -130° C portion of the cooldown, but the meaning of this is somewhat uncertain.

The sternal approximator worked very well, but the edematous lungs had to be inserted back into the chest cavity (as is not uncommon).

Field washout: while the brain cooled quite quickly once perfusion was begun, there was no effect on the rectal temperature. 17 liters of organ preservation solution were pumped into the patient, with some coincident abdominal swelling. Conclusion: while the head was perfused, the body was not, for reasons unknown. Given the clots that the washout surgeon removed from the inferior vena cava, we speculated that there may have been pre-mortem clotting.

8. Timelines

Stabilization (by Suspended Animation)

Thursday, August 18th, 2011, PDT

16:12 Pronouncement
16:13 Ice bath with patient moved into garage
16:14 Autopulse running
16:15 Rectal occluder in
16:16 EZ-IO set
16:18 200mg Propofol in
16:18 50,000 units Heparin in
16:19 250,000 units Streptase in
16:20 300mg Aspirin in
16:20 100 units Vasopressin in
16:20 Ice water recirculation started
16:20 Dual LogR started, nasopharyngeal 36C
16:21 1mg Epinephrine in
16:21 400mg SMT in
16:21 Nasopharyngeal temp probe in
16:22 500mg Niacinimide in
16:24 1mg Epinephrine in
16:24 50ml L Kynurenine in
16:25 50ml L-Kynurenine in
16:25 7.5mg Keterolac in
16:25 Combitube in, ventilator on
16:25 80mg Gentamicin in
16:26 1mg Epinephrine in
16:29 Maalox in
16:30 1mg Epinephrine in
16:33 1ml Epinephrine
16:35 First incision
16:36 Nasopharyngeal temp 35.0C
Rectal temp 38.9C
16:37 THAM in
16:38 1ml Epinephrine in
16:39 Nasopharyngeal temp 34.7C
Rectal 39.0C
16:41 1mg Epinephrine in
16:44 1mg Epinephrine in
16:47 1mg Epinephrine in
16:47 21Fr cannula in venous side
16:50 19Fr cannula placed in artery
16:50 1mg Epinephrine in
16:51 Drainage

16:53 1mg Epinephrine in
 16:57 1mg Epinephrine in
 17:03 Perfusion pump off, venous cannula swapped, clots removed
 17:04 Perfusion pump on
 17:07 Autopulse off – battery swap
 17:07 Nasopharyngeal temp 17.3C
 17:08 Autopulse on
 17:09 Nasopharyngeal temp 13.3C
 17:11 Nasopharyngeal temp 12.7C
 17:15 Abdominal swelling noted
 17:15 Nasopharyngeal temp 11.0C
 17:18 Nasopharyngeal temp 9.9C
 17:20 Nasopharyngeal temp 7.6C
 17:27 Nasopharyngeal temp 6.6C
 17:32 Perfusion pump off

Cryoprotection (by Alcor)

Thursday, August 18th, 2011, MST

22:22 Patient arrived Alcor
 22:33 Patient transferred to operating table, covered in ice
 22:38 Nancy prepped head for burr holes while Aaron prepped chest for separation
 22:55 Nancy made sternal incisions, opened chest, Aaron assisted
 23:00 Aaron spreads chest
 23:07 Nancy and Aaron begin to insert cannula
 23:15 Cannulated right atrium. Very thick atrium and ventricles noted
 23:19 Patient had abnormal heart, bilateral hypertrophy in ventricles, ~4 cm aortic aneurism
 23:26 Cleared bubbles out of tubing
 23:30 Tied off aorta after cannulation
 23:47 Started ramp
 23:51 Mixing reservoir @ 6 liters
 23:53 Nancy made incisions for burr holes
 23:57 Aaron drilled bilateral burr holes, right then left
 23:59 Huge leak from right burr hole, suggesting a subdural hematoma
 00:12 14.2 liters in the dump, 3 liters/4 minutes
 00:21 20.2 liters in the dump, 6 liters/9 minutes
 00:23 Rectal temperature dropped from 25 C to 12 C, indicating some circulation
 00:29 Mixing reservoir volume: 4 liters. Pump speed maxed out.
 00:31 Abdomen distended
 00:47 Switched to neuro step ramp, starting with bag #7
 00:56 88mm perfusion pressure @ 0.75 liters/min.
 01:04 Left jugular located
 01:05 Perfusion stopped to help view surgical field
 01:15 Isolated and raised both carotids
 01:35 Perfusion of neuro restarted. Venous return from left side is good

01:43 Transferred to second bag. 56.68 Brix
 02:04 Steve switched bag
 02:52 Switched bag – last bag
 03:08 Last bag completed
 03:27 Right side of brain retracted 1 cm, left side of brain not retracted
 Both eyes well retracted
 04:03 Begin plunge to -100° C
 04:33 Change Cooldown program to plunge to -80° C
 13:43 Moved patient to pod, restart Cooldown 1° C/hr to LN2

Thursday, August 25th, 2011, MST

00:51 All thermocouple traces flattened out - endpoint
 09:25 Begin LN2 fill
 13:23 Cooldown dewar full

9. Issues and Actions:

Issue: PICC line, although maintained regularly pre-mortem, was no longer patent after pronouncement. No additional intraosseous line was set.

Action: Always set two intraosseous lines (added to protocol and training September 2011).

Issue: Second dose of vasopressin was not given.

Action: Acquire and use low volume, multi-port extension sets to leave epinephrine and vasopressin syringes in place on line with high volume meds for easier administration (Y connector sets acquired October 2011).

Issue: Lower flow and slower cooling through femorals; major thrombi present.

Action: Surgeon recommends acquiring field-appropriate thoracotomy instruments to allow catheterization of aorta and vena cava to speed procedure and cooling. (Portable thoracotomy instruments acquired October 2011).

--End of report --